

Skin Pigmentation Variability in Baboons: Implications for Vitamin D Deficiency

Srishti Sadhir^{1,2,3}, Andrea R. Eller¹, Stephanie L. Canington^{1,4}, Sabrina B. Sholts¹

¹ Department of Biological Anthropology, National Museum of Natural History, Smithsonian Institution, Washington, DC

² Department of Anthropology, University of Connecticut, Storrs, CT

³ Department of Ecology and Evolutionary Biology, University of Connecticut, Storrs, CT

⁴ Center for Functional Anatomy and Evolution, Johns Hopkins University School of Medicine, Baltimore, MD



INTRODUCTION

Zoo primates found in historical museum collections show higher rates of cranial and dental pathologies than their wild counterparts, such as metabolic bone diseases (MBD) attributed to vitamin D deficiency.² When vitamin D is inadequate, calcium and phosphorus from bone tissue are reabsorbed into the bloodstream, and remodeling of mineralized bone causes osteoid buildup and inflammation.^{4,7} Sunlight is the greatest influence on expected vitamin D levels, and insufficient UV exposure leads to the development of a vitamin D deficiency.⁴

Like in humans, recent evidence for baboons has shown that exposed skin pigmentation influences vitamin D₃ levels, with the lowest levels found in the darker subspecies.^{5,8} Here, the relationship between observed MBD in the cranium and skin pigmentation is examined in a historical museum collection of baboons (genus *Papio*). **We hypothesize that the frequency of MBD will differ significantly between individuals of different skin color, with darker subspecies exhibiting higher frequencies.**

MATERIALS AND METHODS

All baboon crania (N=176) at the National Museum of Natural History (NMNH) were surveyed using the EMPHASIS protocol.¹ “Wild” versus “captive” status was identified using specimen tags and the Division of Mammals database. Age was assessed by molar eruption: “Juvenile” as all individuals without M1s fully erupted, “Subadult” as individuals with M1s fully erupted but not M2s, and “Adult” as individuals with M2s fully erupted.

Presence or absence of maxillary thickening and inflammation was the primary indicator for MBD related to vitamin D deficiency (Fig. 1).² Exposed skin color for the subspecies was categorized into “light”, “medium”, and “dark” following Ziegler et al. (2018), including: *P. anubis* and *P. papio* (“dark”), *P. ursinus* and *P. cynocephalus* (“medium”), and *P. hamadryas* (“light”) (Fig. 2).

Figure 1. Differential severity of MBD as represented by maxillary thickening in *Papio* specimens: [a] non-pathological specimen with no evidence of MBD; [b-e] pathological specimens with evidence of MBD. All photographs by Lucia RM Martino, Smithsonian Institution.

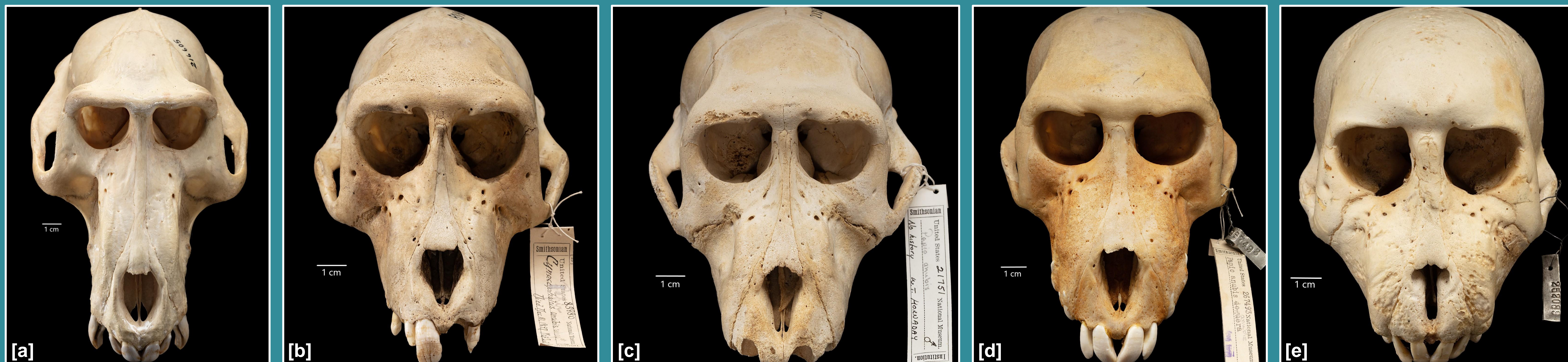

Figure 2. Exposed skin pigmentation in *Papio*: [a] *P. hamadryas* representing the light-skinned pigmentation category (Image: Pixabay); [b] *P. cynocephalus* representing the medium-skinned pigmentation category (Image: University of Dar es Salaam); [c] *P. anubis* representing the dark-skinned pigmentation category (Image: Sharp Photography).

RESULTS

Of all surveyed specimens, 10.2% show maxillary thickening and inflammation indicative of MBD (Table 1). Among captive specimens (n=88), 19.3% exhibited MBD (Table 1). All pathological specimens (n=18) were captive except for one. The chi-square test showed the differences to be statistically significant ($\alpha=0.05$; $p=0.00$), which indicates that a higher frequency of pathological individuals originated from captive environments.

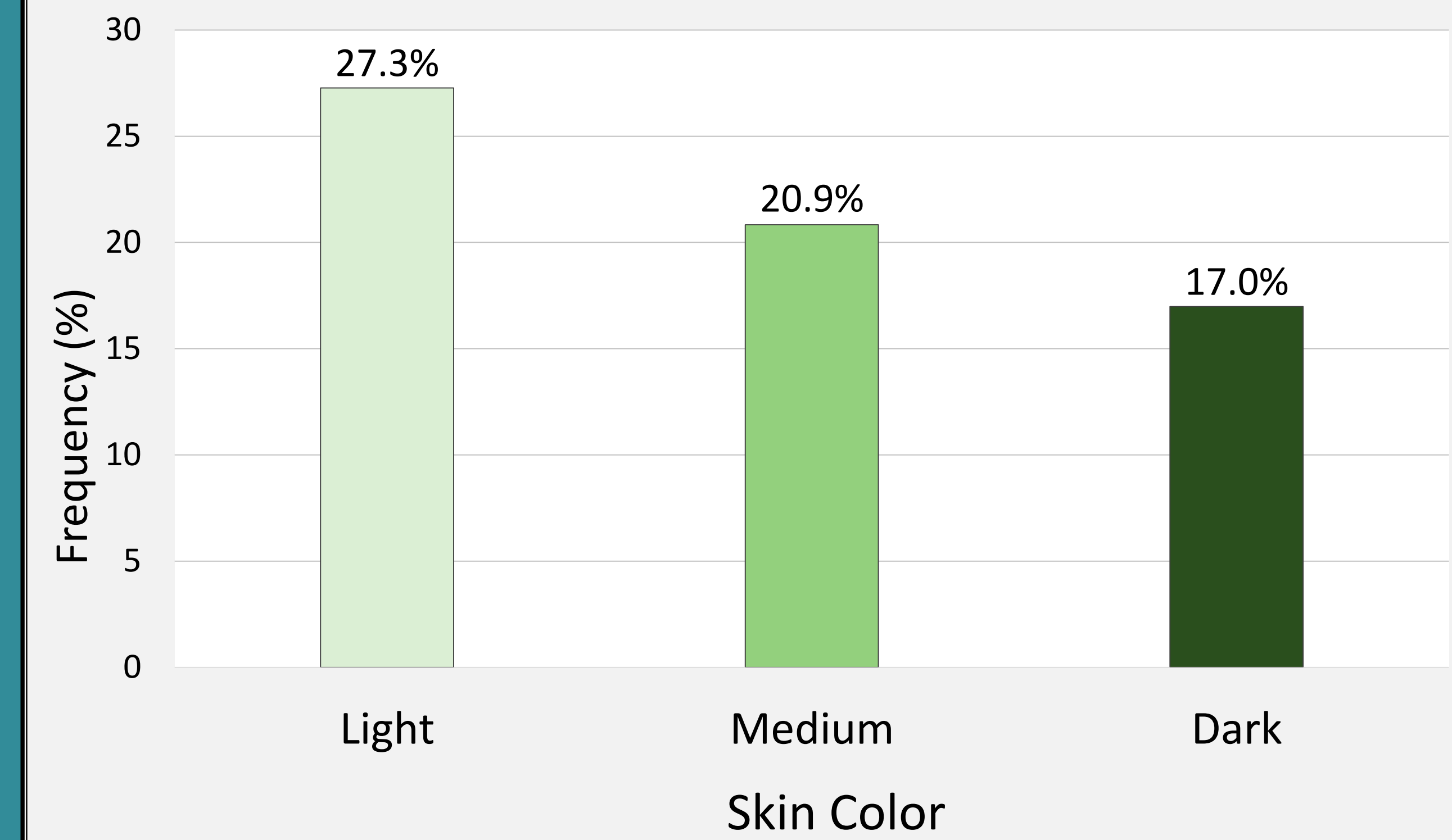
The three skin color categories each illustrate a different frequency of captive individuals with MBD, which was lower in the dark and medium specimens (17.0% and 20.9%, respectively) than the light ones (27.3%) (Fig. 3). However, the chi-square test showed these differences to be not statistically significant ($\alpha=0.05$; $p=0.72$). The results therefore do not support a correlation between skin color and MBD in this sample, nor do they show a higher frequency of MBD in dark-skinned specimens.

Table 1. Summary of *Papio* sample distribution by skin color, captivity status, and MBD

Skin Color	Taxon	Total	Captive	Wild	Total MBD	Captive specimens with MBD	Total % MBD	Captive % MBD
Dark	<i>P. anubis</i> , <i>P. papio</i>	93	53	40	9	9	9.7%	17.0%
Medium	<i>P. ursinus</i> , <i>P. cynocephalus</i>	71	24	47	6	5	8.5%	20.9%
Light	<i>P. hamadryas</i>	12	11	1	3	3	25.0%	27.3%
All skin colors	All taxa	176	88	88	18	17	10.2%	19.3%

Figure 3.

Frequency of MBD in captive *Papio* specimens within each skin color category.



DISCUSSION AND FUTURE DIRECTIONS

The results indicate that skin color and frequency of MBD pathology are not correlated, and darker individuals do not have higher frequencies of MBD. Skin color's role in the development of a vitamin D deficiency may be confounded by other factors. For example, overwhelmingly poor conditions in zoo environments may extinguish any subtle differences in vitamin D absorption based on skin color differences. MBD was predominantly found in specimens that originate from the Smithsonian Institution's National Zoological Park (1897-1940) when zoo captive conditions severely limited adequate sunlight exposure.² Only in recent years have zoos crafted open enclosures for sunlight exposure and begun over-supplementing primates with vitamin D in the diet.⁸

Future studies of the relationships between captivity, skin color, and vitamin D deficiency might include expanding the sample to other museum collections. Ideally, living animals could also help elucidate other important factors such as age and sex in vitamin D synthesis.

ACKNOWLEDGEMENTS

I would like to express my deepest gratitude to my mentors, Sabrina Sholts and Andrea Eller, for their guidance and investment in my NHRE project. Additionally, a heartfelt thanks to the rest of the EMPHASIS project team—Stephanie Canington, George Francis, Courtney Hofman, Rita Austin, Laura Pott, and Mia Ayer—for lending your help and support during these ten weeks. I sincerely appreciate the dedication of NHRE program coordinators, Virginia Power and Gene Hunt, to ensuring the success of this internship program.

Thank you to the National Science Foundation (NSF) for their continued funding of the NHRE program. I am especially grateful to the Smithsonian Women's Committee for their generous funding of my internship experience this summer and commitment to knowledge dissemination.

LITERATURE CITED

- Eller, A. R., Canington, S., Austin, R. M., Hofman, C. A., & Sholts, S. B. (2019). EMPHASIS: Environmental Mismatches in Primates and Humans. *Anthropogenic Settings and Impacts Survey*.
- Farrell, M., Rando, C., & Garrod B. (2015). Lessons from the Past: Metabolic Bone Disease in Historical Captive Primates. *International Journal of Primatology*, 36(2), 398-411.
- Friend, S. R., Eller, A. R., & Sholts, S. B. (2018). The Planet of the Humans? The Effects of Anthropogenic Environments on Great Apes.
- Holick, M. F. (2004). Sunlight and vitamin D for bone health and prevention of autoimmune diseases, cancers, and cardiovascular disease. *The American Journal of Clinical Nutrition*, 80(6), 1678S-1688S.
- Jablonski, N. G. & Chaplin, G. (2000). The evolution of human skin coloration. *Journal of Human Evolution*, 39(1), 57-106.
- Kingdon, J., Happold, D., Butynski, T., Hoffmann, M., Happold, M., & Kalina, J. (2013). *Mammals of Africa Volume II: Primates*. Bloomsbury Natural History.
- Uhl, E. W. (2018). The pathology of vitamin D deficiency in domesticated animals: An evolutionary and comparative overview. *International Journal of Paleopathology*, 23, 100-109.
- Ziegler, T. E., Kapoor, A., Binkley, N. C., Rice, K. S., Rogers, J., Jolly, C. J., & Phillips-Conroy, J. E. (2018). Comparison of vitamin D metabolites in wild and captive baboons. *American Journal of Primatology*, 80(12), 1-11.